Images of the Issue

Demonstration of an inconspicuous right diaphragmatic hernia in a blunt trauma patient using CT multi-planar reformation

Jingshan Gong[1], Kun Qiao[2], Zheng Wang[2], Jianmin Xu[1]

[1]Department of Radiology, Shenzhen People's Hospital, Jinan University Second Clinical Medicine College, Shenzhen, 518020, Guangdong Province China; [2]Department of Thoracic Surgery, Shenzhen People's Hospital, Jinan University Second Clinical Medicine College, Shenzhen, 518020, Guangdong Province China

Corresponding to: Jingshan Gong, MD. Department of Radiology, Shenzhen People's Hospital, Jinan University Second Clinical Medicine College, Shenzhen 518020, Guangdong Province, P.R. China. Tel: +86-755-25533018ext2598(O), +86-13631635669(M); Fax:+86-755-82606036. Email: jshgong@sina.com.

Abstract: The right diaphragmatic hernia is rare and often missed on initial radiological evaluations. Even a small tear in the right diaphragm can be gradually enlarged over time due to pressure differences between the abdominal cavity and thoracic cavity, resulting eventually in the abdominal contents entering into the thoracic cavity. We present a case of inconspicuous right diaphragmatic hernia which was missed at first thoracic radiograph and CT examination. After large portion of some abdominal contents herniated into thoracic cave, CT multi-planar reformation (MPR) demonstrated the changes directly and vividly depicted several signs of diaphragmatic hernia. As CT has become one of most important imaging modalities in the evaluation of thoracic and abdominal trauma, MPR can be used routinely to obtain a definitive diagnosis and improve radiologists' confidence of diaphragmatic hernia.

Key Words: Diaphragmatic hernia; computer tomography; multi-planar reformation

Submitted Aug 01, 2011. Accepted for publication Aug 23, 2011.
DOI: 10.3978/j.issn.2223-4292.2011.08.01
Scan to your mobile device or view this article at: http://www.amepc.org/qims/article/view/17/1

A 27-year-old car crash male victim suffered from short of breath and was hospitalized for observation. On the first day of the traffic accident, chest radiograph showed the blurred right diaphragm (*Figure 1A*), and axial CT showed a suspected collar sign (*Figure 1B*). CT scan was performed on a multi-slice CT (Philips Brainliance 16, Philips Medical System, The Netherlands). Three days later, chest radiograph was obtained again due to continuous thoracic pain and short of breath. The chest radiograph revealed right diaphragm elevation and lost of right costo-diaphragm angle (*Figure 1C*), which was interpreted as a result of pleural effusion and pulmonary atelectasis. Repeated CT scan was carried out. Axial CT images showed the right lobe of liver was dependant against right posterior ribs (dependent viscera sign), waist-like stricture of liver edge (collar sign), and diaphragm thickening (*Figure 1D,E*). Diaphragmatic hernia was suspected and multi-planar reformation (MPR) was performed. On MPR images, diaphragmatic discontinuity, portions of liver and colon were demonstrated in the chest cavity (*Figure 1F*). A definitive diagnosis of right-sided diaphragmatic hernia was established and the patient underwent thoracoscopy assisted diaphragm repair. During the surgery, a central large irregular tear of diaphragm were noted (*Figure 1G*). A large portion of liver and a segment of colon rose into the thoracic cage through the diaphragmatic tear. After all the abdominal contents were moved back into the abdominal cavity, the tear was sewed (*Figure 1H*). The patient recovered well.

Acknowledgements

Disclosure: The authors declare no conflict of interest.

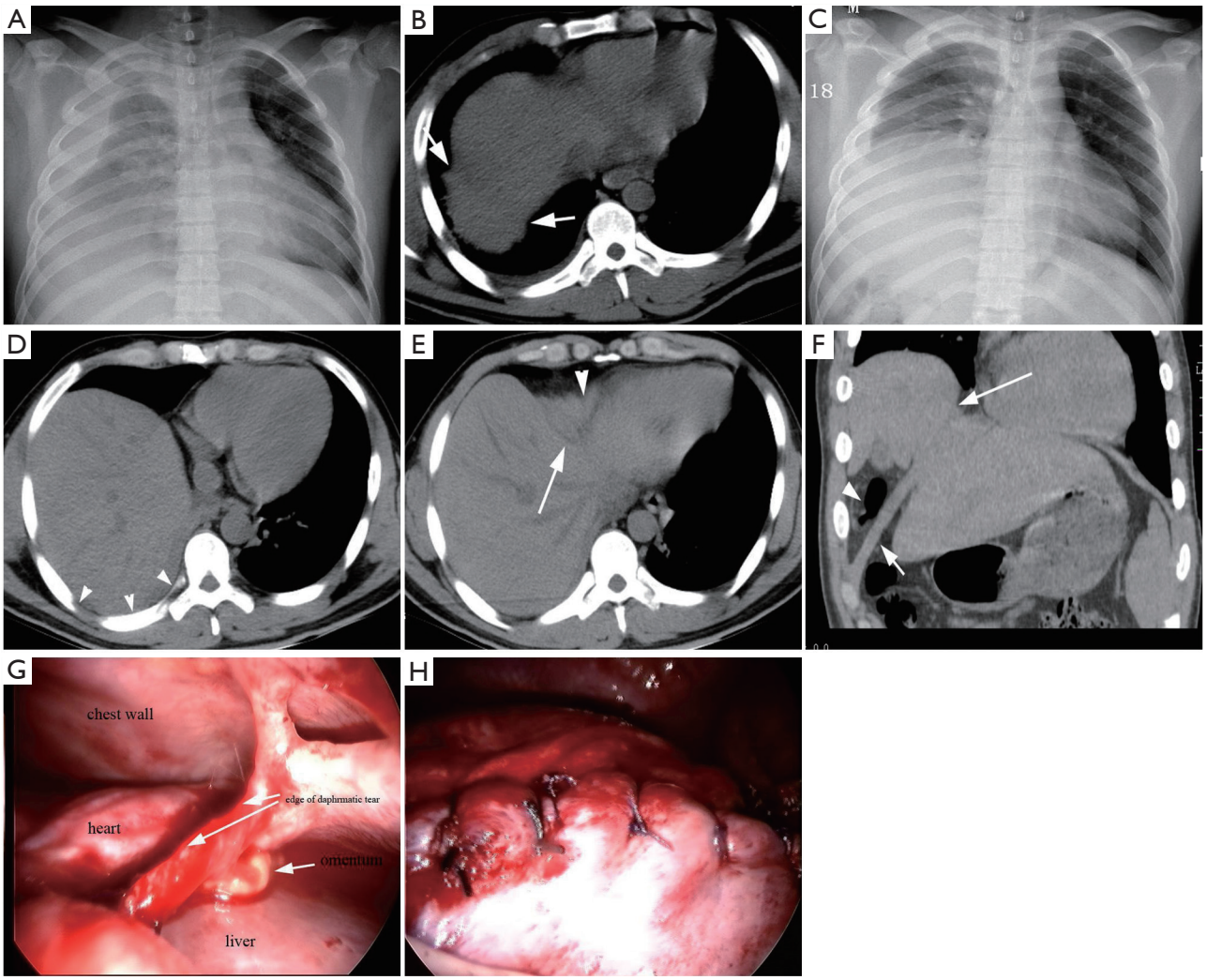

Figure 1 A 27-year-old male with chest pain after a traffic accident. A. Chest radiograph shows a burred right diaphragm; B. Axial CT image demonstrates suspected collar sign (arrows); C. Chest radiograph reveals shows right costo-diaphragm angle lost and right diaphragm elevation; D. Axial CT image reveals dependent viscera sign (arrowheads); E. Axial CT image at more caudal direction to D shows obvious collar sign (arrow) and thickening of diaphragm (arrowhead); F. Coronal MPR shows liver hernias through the tear of the diaphragm with a waist-like stricture (collar sign, long arrow), thickening and discontinuity of diaphragm (short arrow). Hernia of colon (arrowhead) is also noted; G. Photograph under thoracoscopy shows a large tear of the diaphragm; H. Photogragm under thoracoscopy demonstrates the tear is sewed

Cite this article as: Gong J, Qiao K, Wang Z, Xu J. Demonstration of an inconspicuous right diaphragmatic hernia in a blunt trauma patient using CT multi-planar reformation. Quant Imaging Med Surg 2011;1(1):44-45. DOI: 10.3978/j.issn.2223-4292.2011.08.01